

Fungal keratitis

Category(ies): Cornea

Contributor: [Jesse Vislisel, MD](#), [John Chen, MD, PhD](#)

Photographer: Brice Critser, CRA; Carol Chan, CRA; Antoinette Venckus, CRA; Stefani Karakas, CRA

Common feature of fungal keratitis classically include dry-appearing, elevated infiltrates with feathered margins and satellite lesions.

Figure 1

Contributor: [Jesse Vislisel, MD](#)

Photographer: Antoinette Venckus, CRA (1a, 1c); Stefani Karakas, CRA (1b); Brice Critser, CRA (1d)

Rapid progression of culture-positive, fulminant *Fusarium* keratitis over the course of one week. Note the feathered edges, satellite lesions, and large hypopyon. This case required urgent, therapeutic penetrating keratoplasty with anterior chamber washout using amphotericin B and voriconazole to clear the infection.

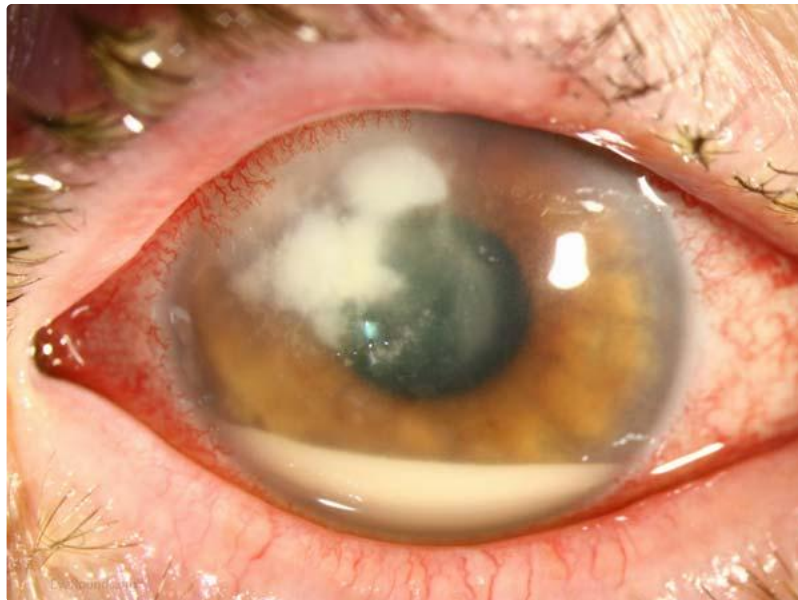


Figure 1a

 [Enlarge](#)

 [Download](#)



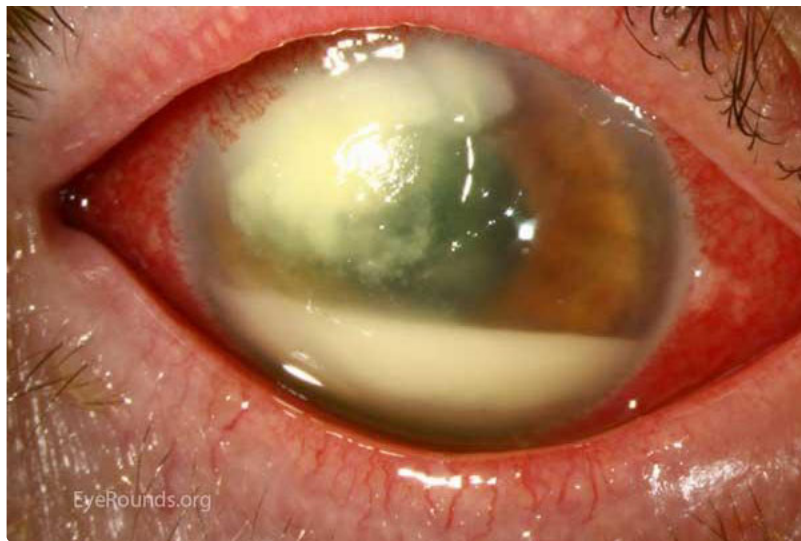

Figure 1b

[Enlarge](#)

[Download](#)

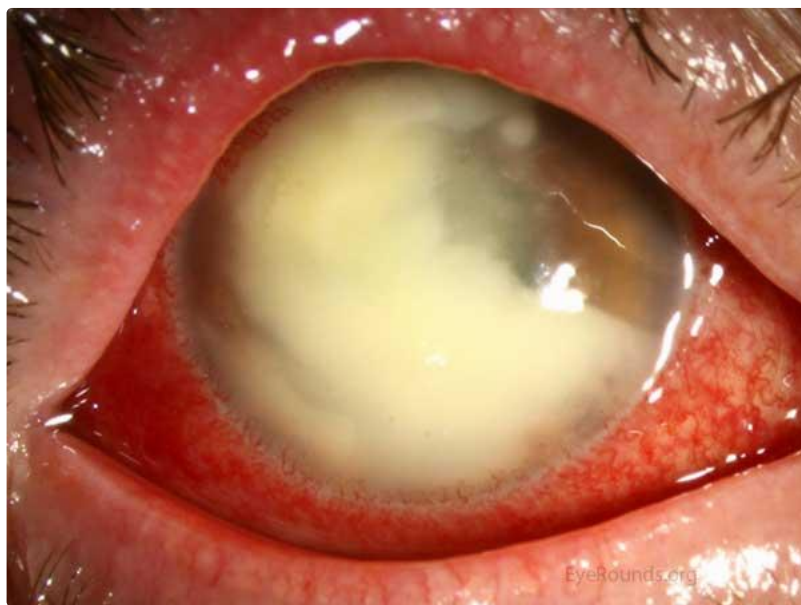

Figure 1c

[Enlarge](#)

[Download](#)

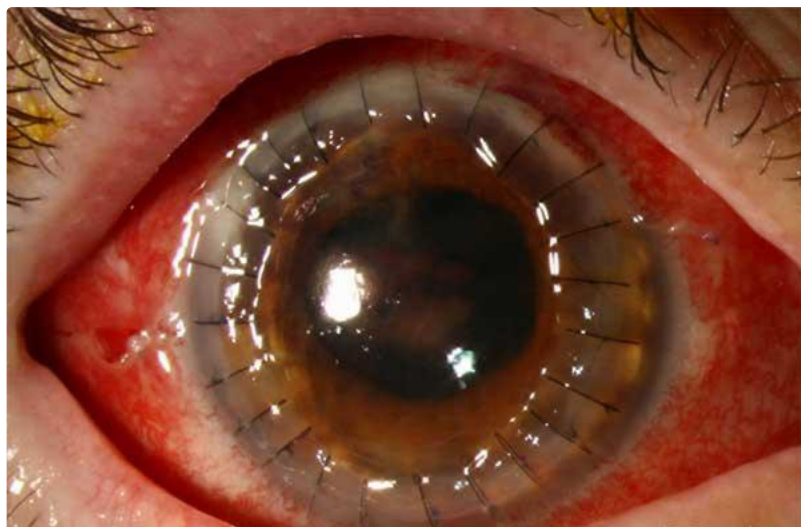

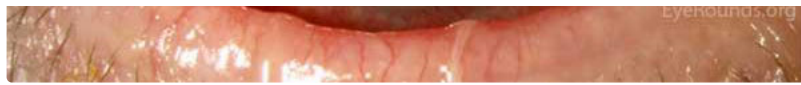


Figure 1d

[Enlarge](#)

[Download](#)

Figure 2

Contributor: [Jesse Vislisel, MD](#)

Confocal microscopy showing branching *Fusarium* filaments in vivo, obtained from the patient in Figure 1 upon her initial presentation.

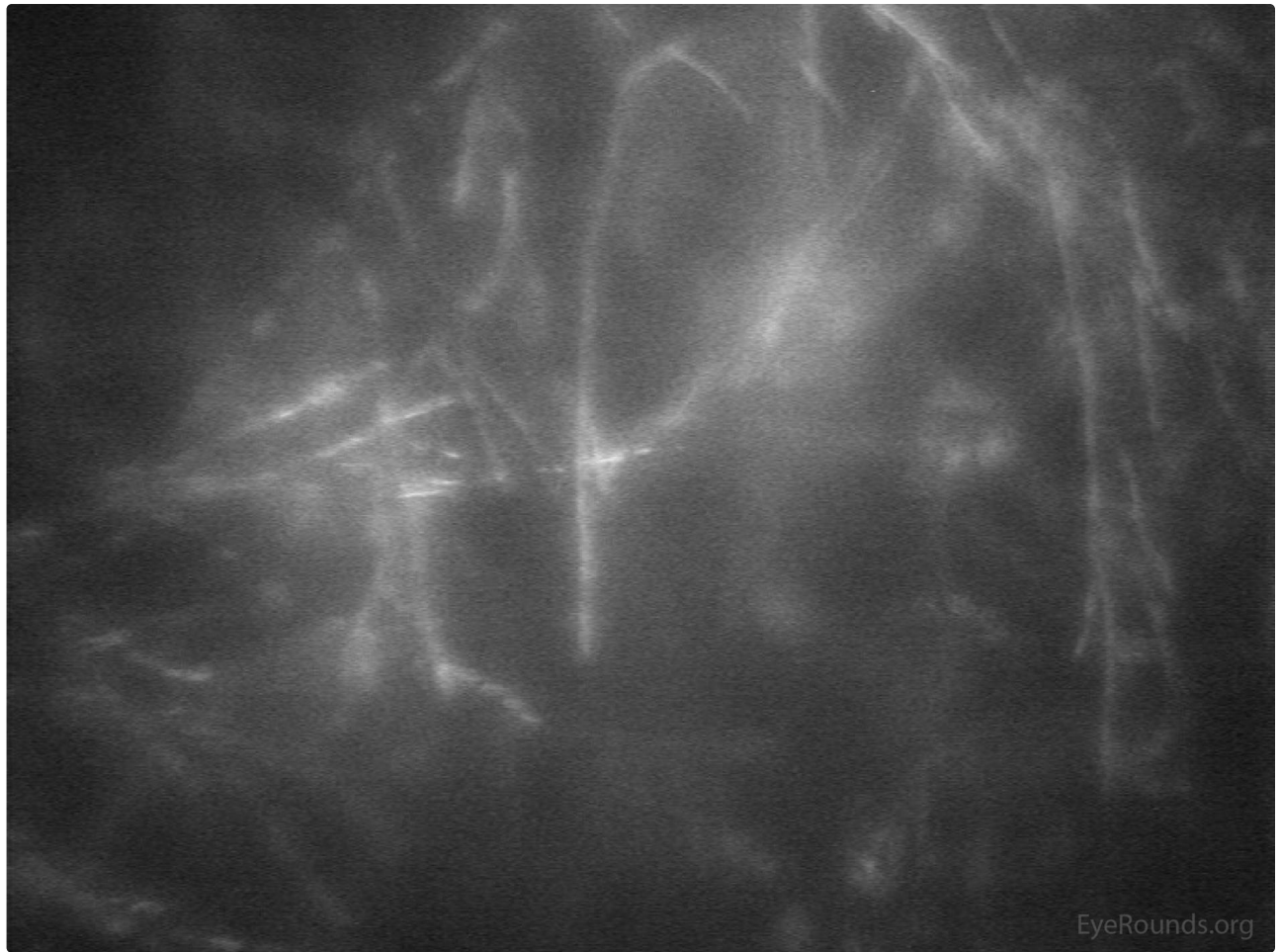


Figure 1d

[Enlarge](#)

[Download](#)

Figure 3

Photographer: [Carol Chan, CRA](#)

Another patient with severe *Fusarium* keratitis, showing a late suppurative appearance mimicking bacterial keratitis. This patient eventually developed intraocular extension and endophthalmitis.

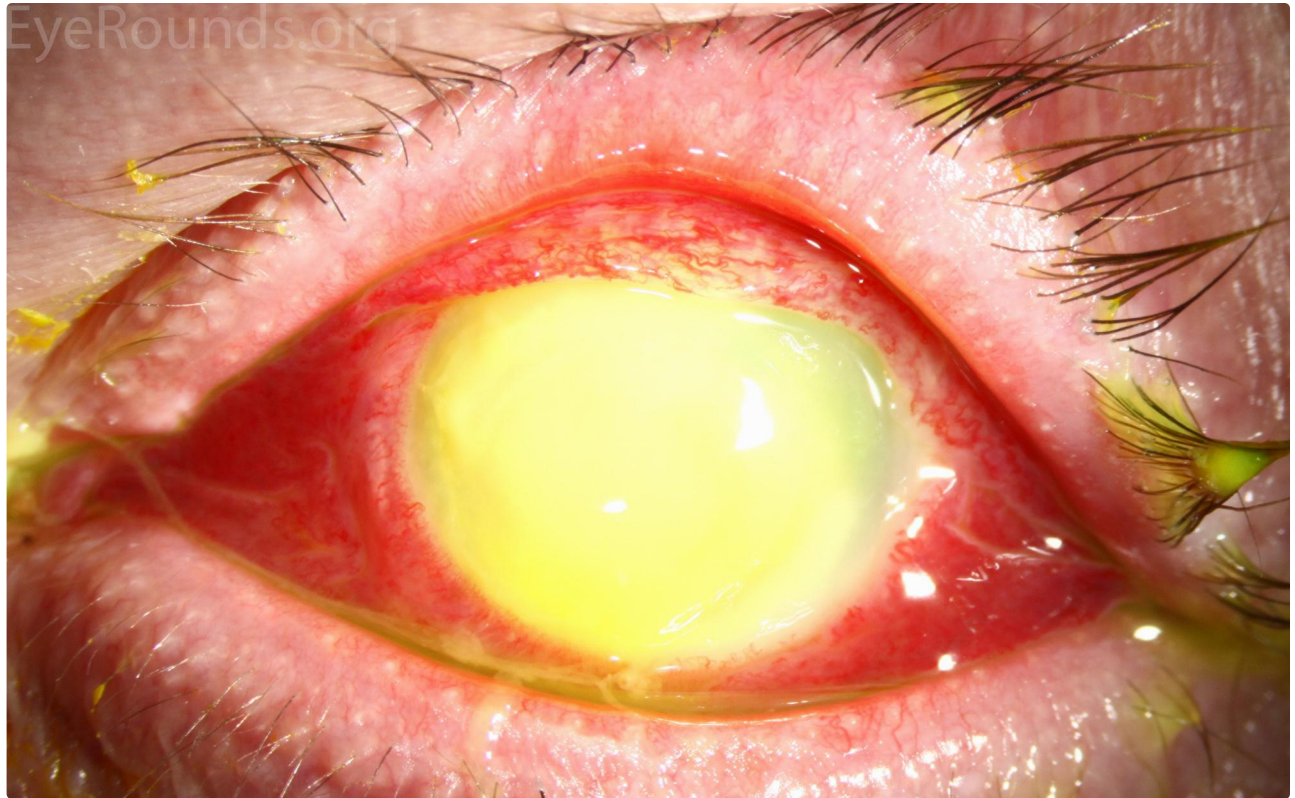


Figure 3a

[Enlarge](#)

[Download](#)

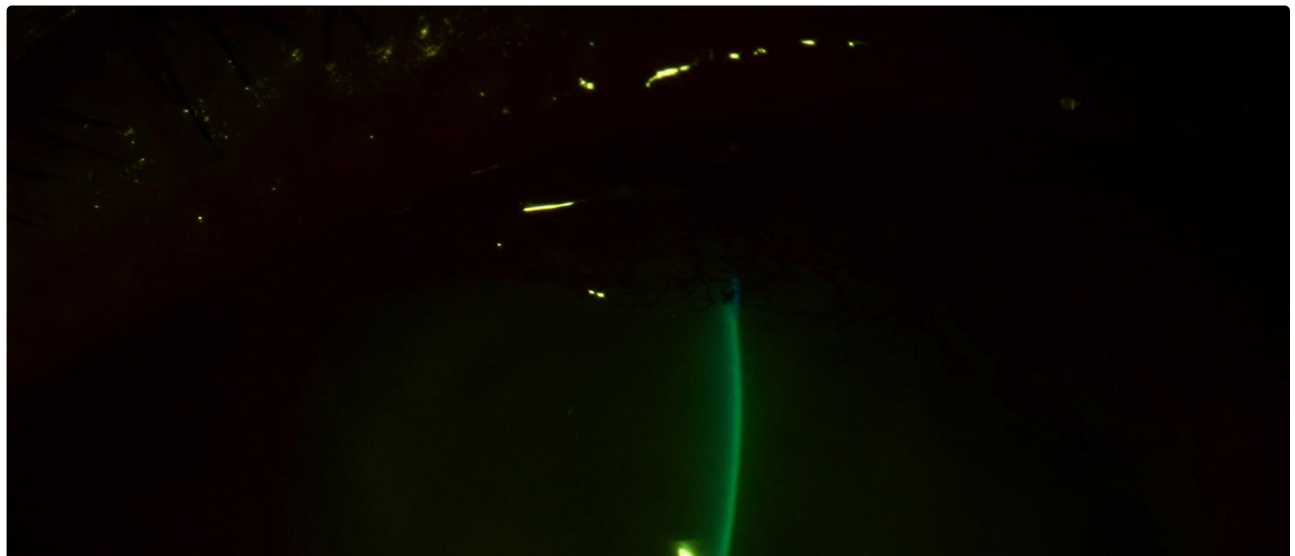

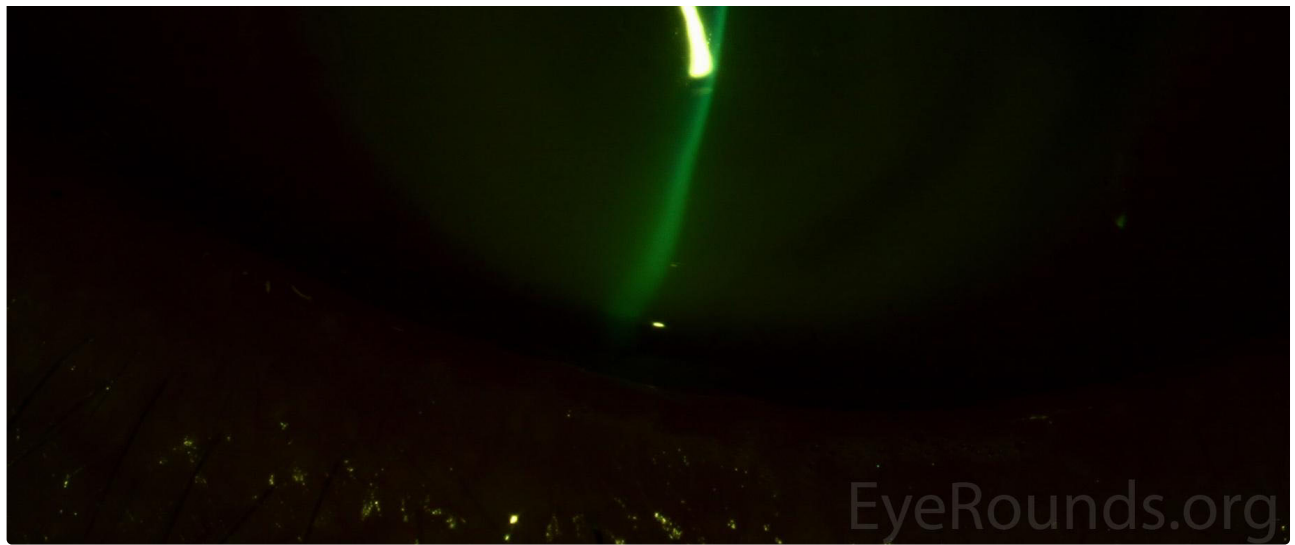


Figure 3b

[Enlarge](#)

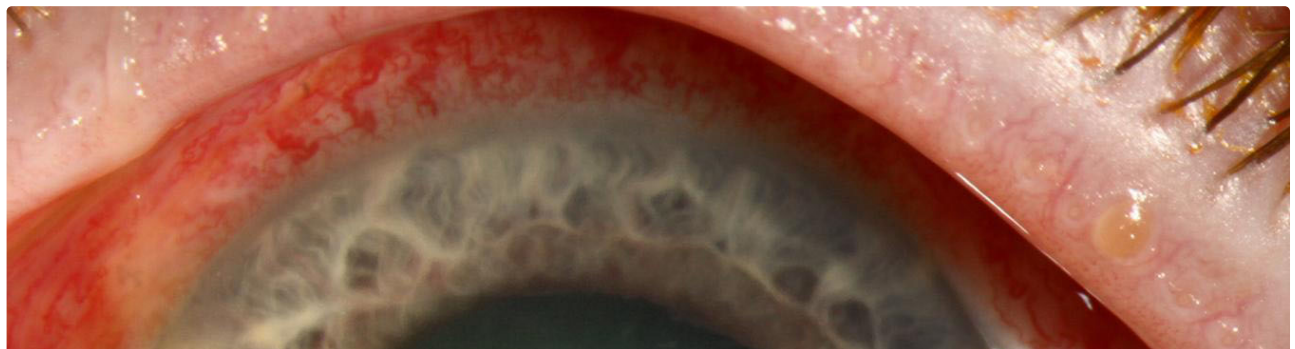[Download](#)

Figure 4

Contributor: [John Chen, MD, PhD](#)

Photographer: Brice Critser, CRA

43-year-old male with fungal keratitis from *Aspergillus*. Note the feathery edges of the infiltrate and the elevated appearance of the lesion, which are commonly seen in fungal keratitis. There is also a 1 mm layered hypopyon



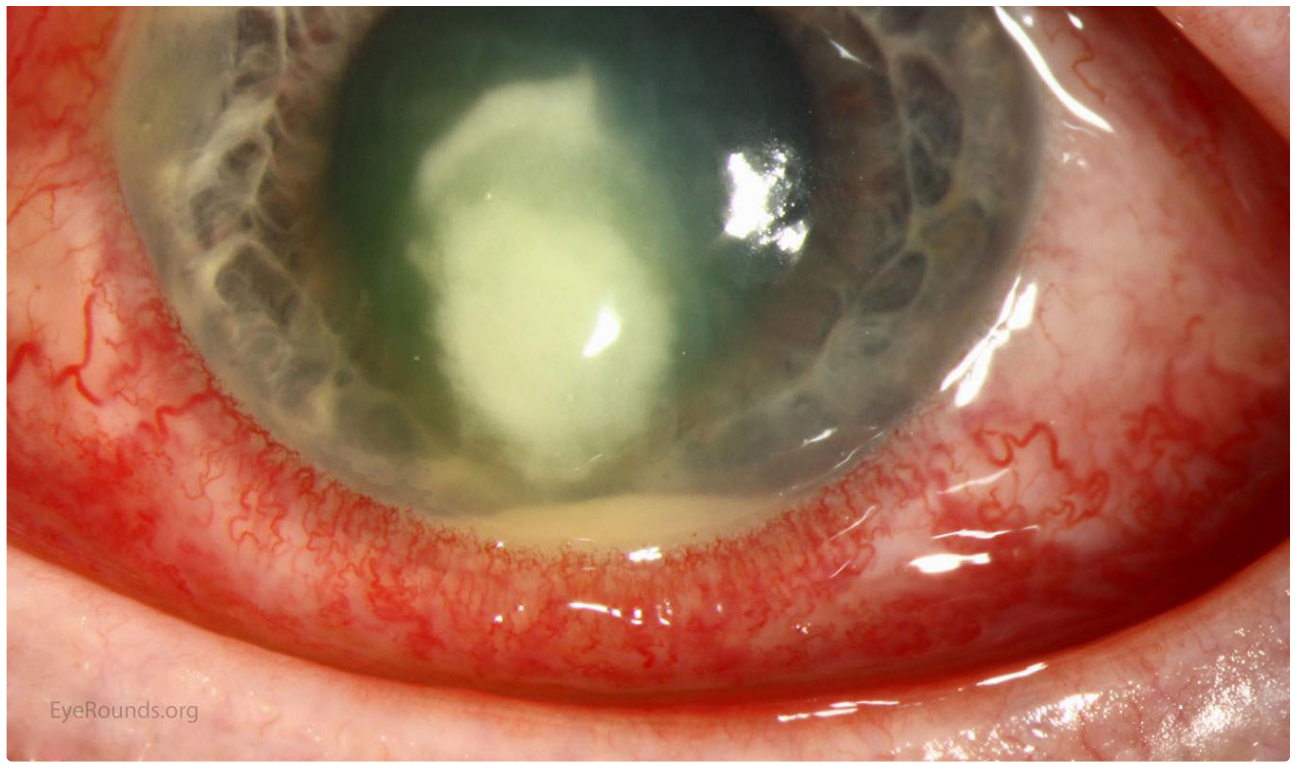

Figure 4

[Enlarge](#) [Download](#)

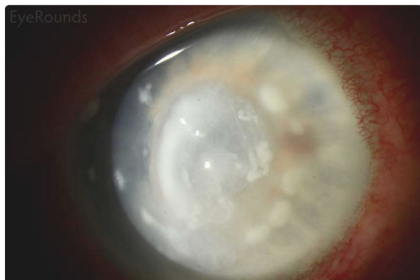Image Permissions:



Ophthalmic Atlas Images by EyeRounds.org, The University of Iowa are licensed under a [Creative Commons Attribution-NonCommercial-NoDerivs 3.0 Unported License](https://creativecommons.org/licenses/by-nc-nd/3.0/).



Related Articles



[Related Atlas Entry: Corneal Satellite Infiltrates](#)

Address

University of Iowa
Roy J. and Lucille A. Carver College
of Medicine
Department of Ophthalmology and
Visual Sciences
200 Hawkins Drive
Iowa City, IA 52242

[Support Us](#)

Legal

Copyright © 2019 The University of
Iowa. All Rights Reserved
[Report an issue with this page](#)
[Web Privacy Policy](#) |
[Nondiscrimination Statement](#)

Related Links

[Cataract Surgery for Greenhorns](#)
[EyeTransillumination](#)
[Gonioscopy.org](#)
[Iowa Glaucoma Curriculum](#)
[Iowa Wet Lab](#)
[Patient Information](#)
[Stone Rounds](#)
[The Best Hits Bookshelf](#)

EyeRounds Social Media

Follow



Receive notification of new cases,
[sign up here](#)
[Contact Us](#)
[Submit a Suggestion](#)